

Awareness about Management of Tooth Avulsion among General Dental Practitioners: A Questionnaire Based Study

Mohammed Mustafa

Department of Conservative Dental Sciences, College of Dentistry, Prince Sattam bin Abdulaziz University, Saudi Arabia

Abstract

Background: Traumatic injuries resulting in avulsion of tooth is common among children and sports personals. This study was planned to explore the awareness of general dental practitioners about the management of an avulsed tooth.

Materials: and methods: This study consist of 148 general dental practitioners who responded to a questionnaire containing 09 validated questions exploring the awareness about the management of avulsion of tooth, which were distributed and the data was collected and entered into the database using the Statistical Package for Social Sciences (SPSS) software version 22. Data were expressed in terms of frequencies and percentages.

Results: Total 148 dental practitioners had answered the questionnaires. Most of the dental practitioners (73%) knew that the avulsed tooth should be saved. Thirty percent of the practitioners were aware of the various factors responsible for the outcome of the tooth replantation.

Conclusion: As most of the dental practitioners lack the proper management protocol, there is need to increase the knowledge of the care of the avulsed tooth and its replantation.

Keywords: Dental trauma; Dental practitioners; Tooth avulsion

Corresponding author:

Dr. Mohammed Mustafa

✉ ma.mustafa@psau.edu.sa

Assistant Professor and Head of Endodontic Division, Department of Conservative Dental Sciences, College of Dentistry, Prince Sattam Bin Abdulaziz University, P.O. Box 153, AlKharj-11942, Kingdom of Saudi Arabia.

Tel: 00966115886240

Citation: Mustafa M. Awareness about Management of Tooth Avulsion among General Dental Practitioners: A Questionnaire Based Study. J Orthod Endod. 2017, 3:1.

Received: December 21, 2016; **Accepted:** January 25, 2017; **Published:** January 30, 2017

Introduction

Trauma to dental structures varies from minor tooth fractures to more extensive dento-alveolar damage involving the supporting structures and displacement of the tooth or tooth avulsion [1]. Dental trauma is a common emergency in dental practice, especially in children and adolescents. From the previous studies it is found that about 10% of the population has experience of the dental trauma in their life, including avulsion of tooth accounting for 1-16% of cases [2,3]. Among different types of dental trauma/injury, tooth avulsion brings about an unexpected functional and esthetic damage to the tooth/teeth because of its poor prognosis. The prognosis of an avulsed tooth relies on three important factors; extra-oral time, storage media and root development. "Parents and school teachers are often the first to attend a child with a tooth avulsion/injury and the medical practitioners are in fact the first to actually provide the primary care/essential treatment" [4].

There may be no single dental problem that has a significant psychological stress/impact on both parent and the child than the actual loss or fracture of a child's anterior teeth. Deciduous and permanent anterior teeth are not only important for aesthetic reason but are also necessary for "phonetics, mastication, integrity of supporting tissues, psychological and mental well-being of children". Sports account for 60% of traumatic dental injuries and schools are the place where one can find an increased risk to these injuries [5,6]. Injuries that affects the dental hard tissues and causes pulpal and periodontal lesions are of incredible importance to present day dentistry, as a result of their frequency, the functional and esthetics disturbances influences that go with them and the rate with which these issues must be dealt with, and fracture of tooth is understood to be the cracking or breaking of a tooth that has been subjected to a force or impact more greater than its resistance [7,8].

Even though endodontic techniques used by the specialist can resolve the pulpal complications caused by the fractured teeth,

the fundamental aspect of prevention must be understood and practiced by the general dentist who will have a complete understanding of the value of rapid action to save the vitality of the pulp [9-11]. Dentists are considered as the essential care takers for them. They are often required to manage traumatic dental injuries in children. Many studies have shown that there is an insufficient knowledge with regards to immediate management to patients with traumatic dental injuries. This particular study was planned to explore the awareness of the dental professionals about the management of an avulsed tooth/teeth [12-14].

Materials and Methods

This study was carried out on 148 general dental practitioners, working in both public and private clinics/hospitals in AlKharj city of Saudi Arabia, with the help of specially prepared questionnaires, which were validated by doing pilot study. Approval of this study was taken from the ethical approval committee, college of dentistry, Prince Sattam Bin Abdulaziz University, AlKharj. The approval was taken before start of the study and an informed consent was taken from all the participants. Questionnaires were consisting of a set of 09 questions. 148 general dental practitioners agreed to fill these questionnaires out of total 175 dental practitioners, and responses from all the 148 participants data were collected and entered into the database using the Statistical Package for Social Sciences (SPSS) software version 22. Data were expressed in terms of frequencies and percentages.

Results

Total 148 dental practitioners had answered the questionnaires. Most of the dental practitioners (73%) were aware of the fact that the avulsed tooth should be saved, but many of them (66%) were not having the knowledge about the management of the avulsed tooth. 58% practitioners say that gentle rinsing with tap water is required to remove the dirt on the surface of the root of avulsed tooth, while 12% advised scrubbing with soap. It is very good to see that 68% know the ideal solution to keep the avulsed tooth i.e., Hanks balanced salt solution. Various factors influence the outcome of the tooth replantation. Thirty percent of the practitioners were aware of the various factors responsible for the outcome of the tooth replantation (Table 1).

Discussion

Dental avulsion is defined as "the complete displacement of a tooth out of its socket along with severed periodontal ligament with or without fracture of the alveolar bone". Being the most serious form of dental trauma, it occurs frequently in the society with an incidence of 0.5-3% of all traumatic dental injuries to the permanent dentition. On tooth avulsion, the "shredding" of the periodontal ligament happens leaving behind viable cells of the periodontal ligament on majority of the root surface [8]. In the present study, 69% of the dental practitioners ready to follow the procedure of replantation of the avulsed tooth. This was also evident in the study by Al-Zubair [9], where 56% dentists willing to re-implant the avulsed tooth.

The determining factors for a favorable prognosis of replantation of avulsed tooth are minimal time of the avulsed tooth outside the socket, the storage and transportation medium of the avulsed tooth, and also minimal handling of the root surface and the periodontal ligament [7-10]. In our study 30% practitioners know the various factors responsible for the outcome of the replanted tooth, which is in accordance to the study by Al-Zubair [9].

Each and every traumatic management of injured tooth/teeth should be guided by use of the best logical proof incorporated with the clinician's skill and the desires of patients and their guardians/parents. However dental practitioners might be "unaccustomed" in both clinical methods and use of research-based data, basically as a result of the infrequent use of such procedures [11].

The epidemiological study conducted by Grossman has reveal that the prevalence of dental avulsion is 2-3 times more common in boys than girls, most probably accredited to their active participation in hostile games and sports of more aggressive nature. Bakland had reported that children in the age group of 8-12 year are more prone to dental accidents, while the teeth commonly involved are maxillary central incisors and lateral incisors. The largest proportions of injuries affecting the permanent dentition are crown fractures. According to Andresen et al., it is the loosely arranged periodontal ligament surrounding the erupting teeth that often display short, incompletely formed roots and the elasticity nature of the alveolar bone which frequently causes the avulsion of these teeth. Clinical appearance of an avulsed tooth is an injury in which tooth is totally out of its socket, and in the radiographic appearance, the fracture lines in socket may or may not be present. "The ideal indication for replantation is avulsed tooth should be without advanced periodontal disease, and the alveolar socket should be reasonably intact in order to provide a seat for the avulsed tooth" [15].

The success for replantation depends on three important factors; extra-oral time, storage medium and root development [16]. Extra-oral time: Universal it is agreed that shorter the extra-oral time better the prognosis for retention of replanted tooth. 90% of replanted teeth with extra-oral time of within 30 min showed no resorption of roots.

Storage media: dry storage results in irreversible injury to the periodontal membrane, "wrapping the tooth in plastic wrap could prevent evaporation for at least 1 h", and storing in the patients saliva is another alternative for shorter periods.

Best storage media is milk, teeth can also be stored in saline or HBSS (Hanks balanced salt solution), research has shown that the best transport medium is cell culture media such as Viaspan or Hanks balanced salt solution, the composition of HBSS; sodium chloride, potassium chloride, calcium chloride, magnesium chloride, sodium bicarbonate, sodium and potassium phosphate.

Other optional storage media includes; contact lens media, cell culture media, EMT tooth saver, propolis [17-19].

Management of the socket

The more careful handling of the socket, the better the prognosis for the replanted tooth, and use of light irrigation and gentle

Table 1: Showing the frequency and percentage responses of the general dental practitioners to the questionnaires related to dental avulsion.

S. No.	Questionnaires	Frequency	Percentage
Q1.	What will you do if you have found patient with avulsed tooth outside the oral cavity?		
	a. Save.	108	73%
	b. Discard.	15	10%
	c. Don't know what to do.	25	17%
Q2.	Do you have information of the management of avulsed tooth?		
	a. Yes.	98	66%
	b. No.	50	34%
Q3.	What would you do if the avulsed tooth was covered with dirt?		
	a. Rinse with tap water.	86	58%
	b. Would do nothing.	35	24%
	c. Scrub with soap.	18	12%
	d. Not sure.	09	6%
Q4.	According to you which are the best storage medium for the storage of the avulsed tooth?		
	a. Hanks balanced salt solution.	101	68%
	b. Milk.	31	21%
	c. Saliva.	09	06%
	d. Saline solution.	07	05%
Q5.	Would you prefer the replantation of the tooth in to the socket from which it came?		
	a. Yes.	102	69%
	b. No.	46	31%
Q6.	Which is the critical time for the replantation of the avulsed tooth?		
	a. Less than 30 min.	66	45%
	b. Less than 60 min.	52	35%
	c. Less than 90 min.	16	11%
	d. More than 90 min.	14	09%
Q7.	Factors influencing the outcome of the replantation?		
	a. Storage medium.	40	27%
	b. Extra-alveolar time period.	48	32%
	c. Amount of the loss of periodontal ligaments.	16	11%
	d. All of the above.	44	30%
Q8.	Tooth which method of splinting after replantation will you prefer?		
	a. Stainless steel wire.	50	34%
	b. Semi-rigid with nylon wire.	34	23%
	c. Composite restorative materials.	36	24%
	d. No splinting.	28	19%
Q9.	Splinting time necessary?		
	a. 15 days.	58	39%
	b. 30 days.	56	38%
	c. 60 days.	34	23%

aspirations to remove any blood clot present in the socket so as to permit replantation, never curette the socket to promote bleeding and thereby helps in healing [20-23].

Management of the root surface

To preserve the viability of the root surface cells, do not scrape, brush, or remove any part of the root surface, if the root surface appears to be clean, replant as it is or if the root surface is dirty, rinse and clean it with tap water.

When to perform endodontic treatment

The guidelines suggest that the root canal treatment should be commenced within 7-14 days of replantation and when the avulsed tooth is in its own socket.

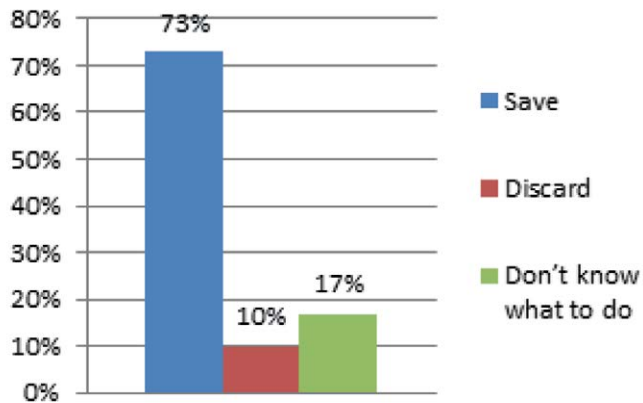
Splinting

Leaving the splint in place for 7-10 days if no bony fractures are present or longer if necessary, and inform the patient not to chew on the splinted teeth; and always prescribe soft diet till the splints are present in the mouth.

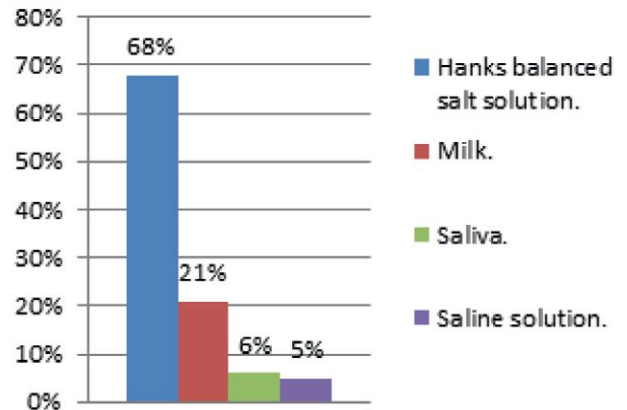
Supportive drug therapy

The patient should be referred to a physician for a tetanus consultation within the first 48 h, and prescribe analgesics to relieve pain and antibiotics only if indicated.

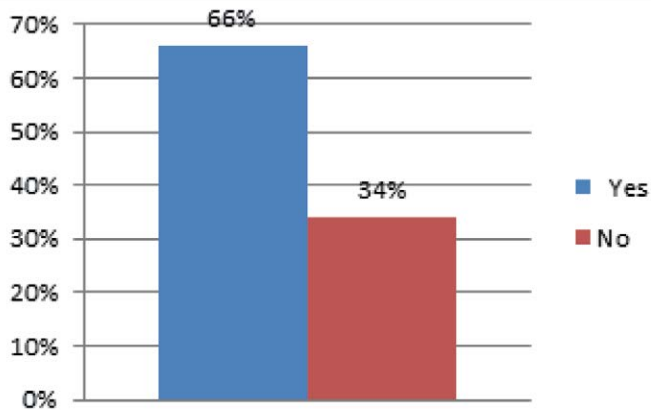
Instructions to the patient: Soft diet, brush with soft brush gently, use of chlorhexidine mouth wash (0. 1%) for 7 days and regular follow up to be maintained.



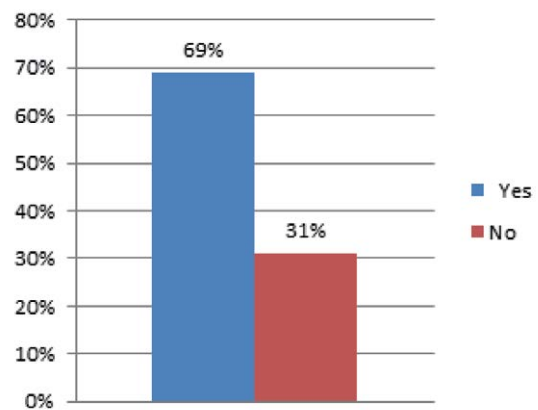
Graph 1 Showing the percentage response to the question no. 1, what will you do if you have found a patient with an avulsed tooth outside the oral cavity?.



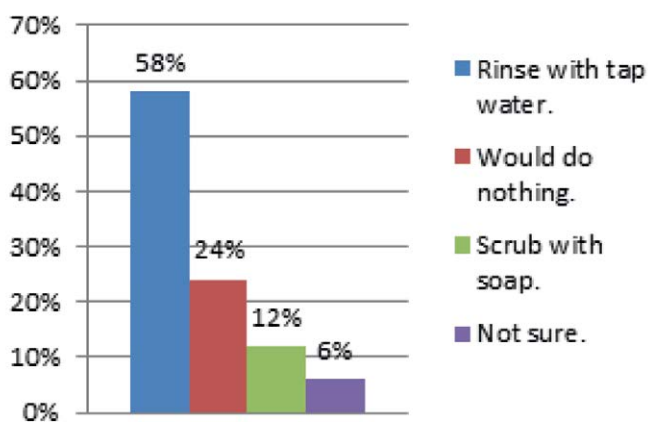
Graph 4 Showing the percentage response to the question no. 4, According to you which are the best storage medium for the storage of the avulsed tooth?.



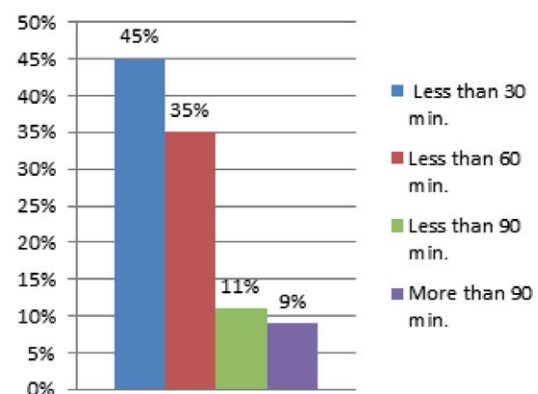
Graph 2 Showing the percentage response to the question no. 2, Do you have information of the management of avulsed tooth?.



Graph 5 Showing the percentage response to the question no. 5, Would you prefer the replantation of the tooth in to the socket from which it came?



Graph 3 Showing the percentage response to the question no. 3, what would you do if the avulsed tooth was covered with dirt?.



Graph 6 Showing the percentage response to the question no. 6, which is the critical time for the replantation of the avulsed tooth?.

Treatment of Avulsed Tooth

If the avulsed tooth is less than 30 min out of the socket; “rinse with physiologic solution, clear debris on the root surface, and flush the socket with sterile water or saline, and then replant the tooth in its socket and splint”. If the avulsed tooth is out of the socket between 30 min to 6 h in a wet medium; “place the tooth in HBSS (Hanks Balanced Salt Solution) for 30 min, and flush the socket with sterile water or saline, and then replant the tooth and splint it in functional position” [24-27].

Greater than 1 h if the avulsed tooth is in dry storage; “remove the remnants of PDL fibers and soak the tooth in sodium hypochlorite solution for 10-15 min, followed by root canal preparation outside the mouth, soak the tooth in 2% stannous fluoride or sodium fluoride solution for 5 min, coat the root surface with emdogain and place emdogain in the socket and replant the tooth, and splint it in functional position”.

Before replanting, “remove the coagulum from the socket with the help of saline, examine the socket properly, If the socket wall is fractured, relocate the fracture with appropriate instruments”. The tooth should be replanted in its socket using light digital pressure, suture gingival lacerations if present and splinting is always mandatory [28].

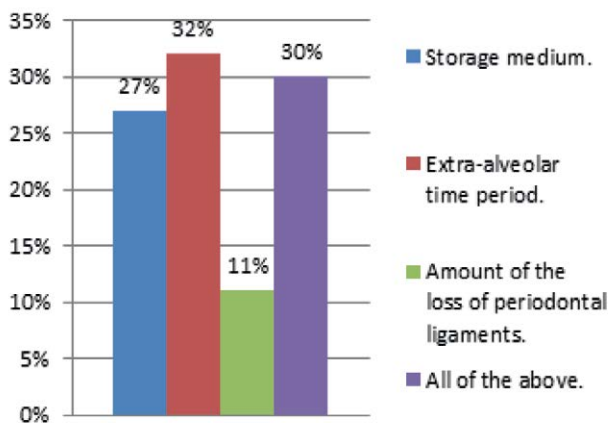
Complication of tooth avulsion: Root resorption, Ankylosis.

Conclusion

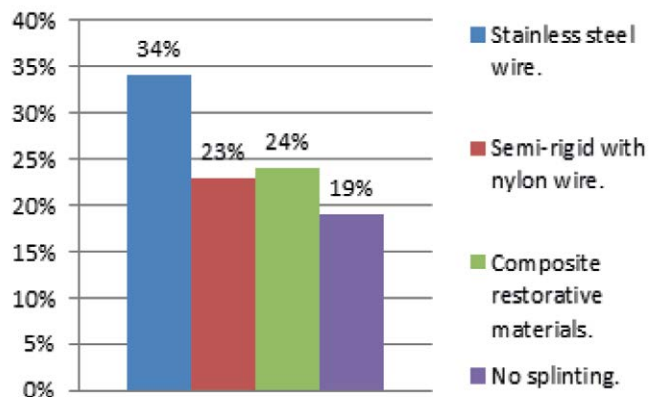
It is very important to save the avulsed tooth as it can affect the social, mental and physical health of the patient. From the above study it can be concluded that most of the general dental practitioners are aware but lacks the proper management protocol of the avulsed tooth. Therefore various seminars, continuous dental education programme or workshops should be conducted so as to increase their awareness in a proper prescribed management of tooth avulsion.

Acknowledgement

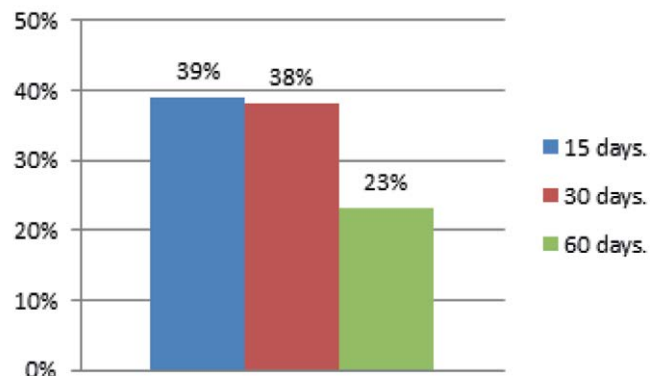
The author is thankful to all those interns belonging to our college of dentistry who helped in conducting this study.



Graph 7 Showing the percentage response to the question no. 7, Factors influencing the outcome of the replantation?.



Graph 8 Showing the percentage response to the question no. 8, Tooth which method of splinting after replantation will you prefer?.



Graph 9 Showing the percentage response to the question no. 9, Splinting time necessary?.

References

- 1 Krishnan B, Joseph J (2014) Knowledge of basic dental physiology among teachers can improve preliminary management of acute dental avulsion in school children. *Int J Clin Exp Physiol* 1: 63-67.
- 2 de Lima Ludgero A, de Santana Santos T, Fernandes AV, de Melo DG, Peixoto AC, et al. (2012) Knowledge regarding emergency management of avulsed teeth among elementary school teachers in Jabotão dos Guararapes, Pernambuco, Brazil. *Indian J Dent Res* 23: 585-590.
- 3 Andreasen JO and Andreasen FM (1994) Textbook and color atlas of traumatic injuries to the teeth (3rd edn.). Copenhagen: Munksgaard.
- 4 Khandelwal V, Gupta A, Khandelwal S (2013) Awareness about management of 'avulsed teeth' among primary contact doctors. *J of Ind Asso of Pediat Surg* 18: 93.
- 5 Pujita C, Nuvvula S, Shilpa G, Nirmala S, Yamini V (2013) Informative promotional outcome on school teachers' knowledge about emergency management of dental trauma. *J Conserv Dent* 16: 21-27.
- 6 Kaur H, Kaur S, Kaur H (2012) Prehospital emergency management of avulsed permanent teeth: Knowledge and attitude of school teachers. *Indian J Dent Res* 23: 556.
- 7 Loo TJ, Gurunathan D, Somasundaram S (2014) Knowledge and attitude of parents with regard to avulsed permanent tooth of their children and their emergency management-Chennai. *J Indian Soc Pedod Prev Dent* 32: 97-107.
- 8 Singh M, Singh N, Dhiman RK, Kumar D (2013) External replacement resorption in avulsed reimplanted permanent incisors. *J Int Clin Dent Res Organ* 5: 27-30.
- 9 Al-Zubair NM (2015) General dentists knowledge about the emergency management of dental avulsion in Yemen. *Saudi J Oral Sci* 2: 25-29.
- 10 Kenny DJ, Barrett EJ, Casas MJ (2003) Avulsions and Intrusions: The Controversial Displacement Injuries. *J Can Dent Assoc* 69: 308-313.
- 11 Petti S, Tarsitani G (1996) Traumatic injuries to anterior teeth in Italian schoolchildren: prevalence and risk factors. *Dent Traumatol* 12: 294-297.
- 12 Panzarini SR, Pedrini D, Brandini DA, Poi WR, Santos MF, et al. (2005) Physical education undergraduates and dental trauma knowledge. *Dent Traumatol* 21: 324-328.
- 13 Trope M, Friedman S (1992) Periodontal healing of replanted dog teeth stored in Viaspan, milk and Hank's balanced salt solution. *Endod Dent Traumatol* 8: 183-188.
- 14 Levin L, Zadik Y (2012) Education on and prevention of dental trauma: it's time to act!. *Dent Traumatol* 28: 49-54.
- 15 Hashim R (2012) Investigation of mothers' knowledge of dental trauma management in United Arab Emirates. *Europ Arch of Paedia Dent* 13: 83-86.
- 16 Sharma D, Garg S, Sheoran N, Swami S, Singh G (2011) Multidisciplinary approach to the rehabilitation of a tooth with two trauma episodes: systematic review and report of a case. *Dent Traumatol* 27: 321-326.
- 17 Frujeri MLV, Costa ED Jr (2009) Effect of a single dental health education on the management of permanent avulsed teeth by different groups of professionals. *Dent Traumatol* 25: 262-271.
- 18 Mori GG, Janjác como DMM, Castilho LR, Poi WR (2009) Evaluating the knowledge of sports participants regarding dental emergency procedures. *Dent Traumatol* 25: 305-308.
- 19 Castilho LR, Sundefeld LMMM, de Andrade DF, Panzarini SR, Poi WR (2009) Evaluation of sixth grade primary schoolchildren's knowledge about avulsion and dental reimplantation. *Dent Traumatol* 25: 429-32.
- 20 Glendor U (2009) Has the education of professional caregivers and lay people in dental trauma care failed?. *Dent Traumatol* 25: 12-18.
- 21 Traebert J, Traiano ML, Armênio R, Barbieri DB, de Lacerda JT, et al. (2009) Knowledge of lay people and dentists in emergency management of dental trauma, *Dent Traumatol* 25: 277-283.
- 22 Jorge KO, Ramos-Jorge ML, de Toledo FF, Alves LC, Paiva SM, et al. (2009) Knowledge of teachers and students in physical education's faculties regarding first-aid measures for tooth avulsion and replantation. *Dent Traumatol* 25: 494-499.
- 23 Santos MESM, Habecost APZ, Gomes FV, Weber JBB, de Oliveira MG (2009) Parent and caretaker knowledge about avulsion of permanent teeth. *Dent Traumatol* 25: 203-208.
- 24 Judy DM, Lee JY, Trope M, Vann WF (2008) Effectiveness of dental trauma education for elementary school staff. *Dent Traumatol* 24: 146-150.
- 25 McIntyre JD, Lee JY, Trope M, Vann WF (2008) Elementary school staff knowledge about dental injuries. *Dent Traumatol* 24: 289-298.
- 26 Al-Asfour A, Andersson L (2008) The effect of a leaflet given to parents for first aid measures after tooth avulsion. *Dent Traumatol* 24: 515-521.
- 27 Krasner P, Rankow H (1995) New philosophy for the treatment of avulsed teeth. *Oral Surg Oral Med Oral Pathol* 79: 616-623.
- 28 Panzarini SR, Gulinelli JL, Poi WR, Sonoda CK, Pedrini D (2008) Treatment of root surface in delayed tooth replantation: a review of literature. *Dent Traumatol* 24: 277-282.