

## Correction of Class II Malocclusions in Growing Patients by Using the Invisalign® Technique: Rational Bases and Treatment Staging

**Aldo Giancotti\*, Paola Pirelli and Gianluca Mampieri**

Department of Orthodontics, University of Rome Tor Vergata, Rome, Italy

**Received:** June 30, 2017; **Accepted:** September 13, 2017; **Published:** September 20, 2017

**\*Corresponding author:** Aldo Giancotti

**Keywords:** Class II; Clear aligners; Invisalign; Biomechanics

✉ giancott@uniroma2.it

### Introduction

Over the past two decades, several articles have demonstrated that the prevalent skeletal feature in Class II patients consists of mandibular retrusion [1-7]. For such reason, an effective universally accepted treatment strategy is based on promoting a mesial repositioning of the mandible to correct the Class II relationship. Moreover, from a dental analysis, it has been shown that up to 85% of Class II patients' present mesial rotation of their maxillary 1st and 2nd molars. One cause for displacement of molars is the mesial movement into the leeway space left during transition from mixed to permanent dentition [8,9]. This creates a loss of arch length and results in mesial rotation of the remaining dentition anteriorly, creating a Class II cuspid relationship and increased overjet. In Class II div. 2, there is a palatal version of the central upper incisors with reduced overjet and limited mandibular advancement. Hence, any appliance that demonstrates the ability to significantly stimulate mandibular growth would be an important asset to a clinician's armamentarium [10-13]. More recently, clear aligner technology has evolved over the past 10 years with such appliances continuously being modified to broaden the range of tooth movements they can achieve [14]. Nowadays, it is possible to correct every type of malocclusion by using aligners: deep bite, open bite, cross bites, severe crowding, Class II and Class III malocclusions [15-17]. In literature, a number of scientific articles including case reports show proper correction of Class II malocclusions by using aligners. However, treatment protocols are not so clearly evidenced at times so as to allow for a standardization and simplification of such orthodontic treatments, which would implement success rate [18-22]. The aim of this work is to show how it is possible to treat Class II malocclusions by means of aligners according to suggested treatment protocols herein.

Department of Orthodontics, University of Rome Tor Vergata, Rome, 00198 Italy.

**Tel:** +068845946

**Citation:** Giancotti A, Pirelli P, Mampieri G (2017) Correction of Class II Malocclusions in Growing Patients by Using the Invisalign® Technique: Rational Bases and Treatment Staging. J Orthod Endod. Vol. 3 No. 4:12

1. Correct any mesial rotation of upper 1st molars;
2. Expand the maxillary archform;
3. Coordinate the upper and lower archforms;
4. Overcorrect the maxillary incisor lingual torque;
5. Use Class II elastics.

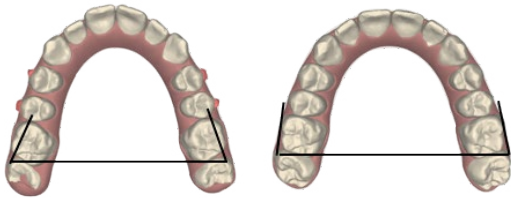
In our experience with aligners, orthodontic correction of mild to moderate Class II malocclusions may be managed both predictably and efficiently by complying to the same biomechanical requirements as in conventional orthodontics. Furthermore, aligners can provide an additional advantage allowing greater freedom of movement of the mandible and, thus, facilitating a mandibular mesial repositioning. Obviously, it is important to carefully evaluate the etiology of Class II relationships. If one determines that the malocclusion does not depend on a real skeletal discrepancy but rather on dental-skeletal problems, it is possible to plan the strategic biomechanical steps to correct it by using aligners. The treatment protocol for Class II malocclusion treatment with aligners includes the same 5 steps mentioned above:

1. Correct any mesial rotation of upper 1st and 2nd molars. The correction of mesial rotations may open up to 2 mm of space per side for subsequent distalization of bicuspid and canines. Request the buccal surfaces of the upper molars

### Rational Approach to Class II Correction

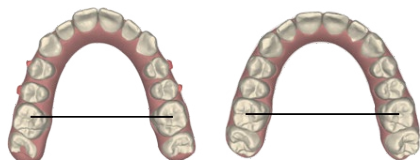
When clinicians decide to treat a Class II malocclusion by means of fixed appliances, they conventionally follow the biomechanical steps below:

to be nearly parallel to each other on the ClinCheck®. Subsequently, determine the treatment plan and consider that molar rotation with aligners alone is a highly predictable movement (**Figure 1**).



**Figure 1** Molar rotation evaluation.

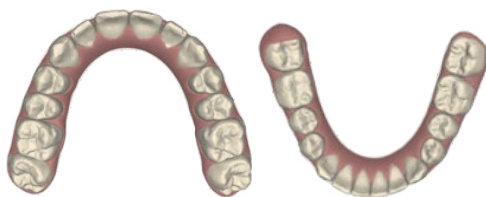
- Expand the maxillary archform to gain any further space needed for possible distalization of bicuspids and canines into Class I relationships. Class II malocclusions have a relative maxillary transversal discrepancy related to the mandibular arch. According to the aforementioned mechanics required for Class II correction, the maxillary teeth need to be directed towards a wider section of the dental arch during treatment. Our experience suggests to ask for 2 mm of buccal overjet on all teeth, excluding a “socked-in” occlusion at the end of the ClinCheck® treatment plan. The reasoning behind this preference is that the amount of expansion indicated on the ClinCheck® treatment plan may not clinically occur, especially when using a lot of Class II elastic wear, which exerts a constrictive force on the maxillary arch (**Figure 2**).



Pre \_\_\_\_\_  
Post \_\_\_\_\_

**Figure 2** Expansion of the maxillary archform.

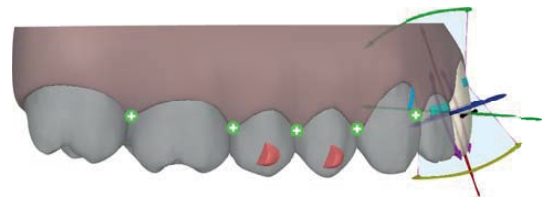
- Coordinate the upper and lower archforms. This step is a necessary consequence of the previous one, and allows to reach an appropriate match between the two arches to encourage mesial repositioning of the mandible (**Figure 3**).



**Figure 3** Archforms coordination.

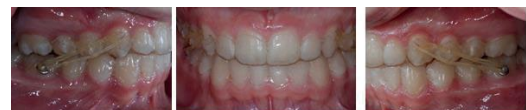- Overcorrect maxillary incisor lingual torque. Anterior lingual root torque is another movement that shall be overprescribed in the ClinCheck® for the movement to clinically occur. Firstly, diagnose how much torque is required based on cephalometric measurement, and

then ask the technician to add to this amount 5° within the ClinCheck® treatment plan. For example, if the upper incisors require 10° of lingual root torque, ask the technician to add 15° of lingual root torque. Otherwise, clinicians will be able to set up their own model by using the innovative tool, ClinCheckPro®. If accurately followed, indications by the program are strategic to favor the mesial positioning of the mandible in both Class II div. 2 and div. 1 malocclusions (**Figure 4**).



**Figure 4** Final incisor torque assessment.

- Use of Class II elastics is required from the very beginning for proper Class II correction. Elastics are tied from a precision cut in the upper aligner to the bonded metal button on the buccal surface of the lower first molars with 4 oz, 3/16 size elastics, to improve upper molar distal rotation and sequential distalization of bicuspids and canines. Moreover, if we intend to minimize the constriction effect on the upper arch and the consequent loss of incisor torque, the elastics can be tied from a clear bonded button onto the crown surface of the upper canines to the button on the lower first molars. An important advantage of such orthodontic technique consists of aligners preventing the extrusion of the teeth despite the use of Class II elastics and, therefore, enable suitable verticality control (**Figure 5**).



**Figure 5** Class II elastic use for A-P correction.

## Clinical Reports

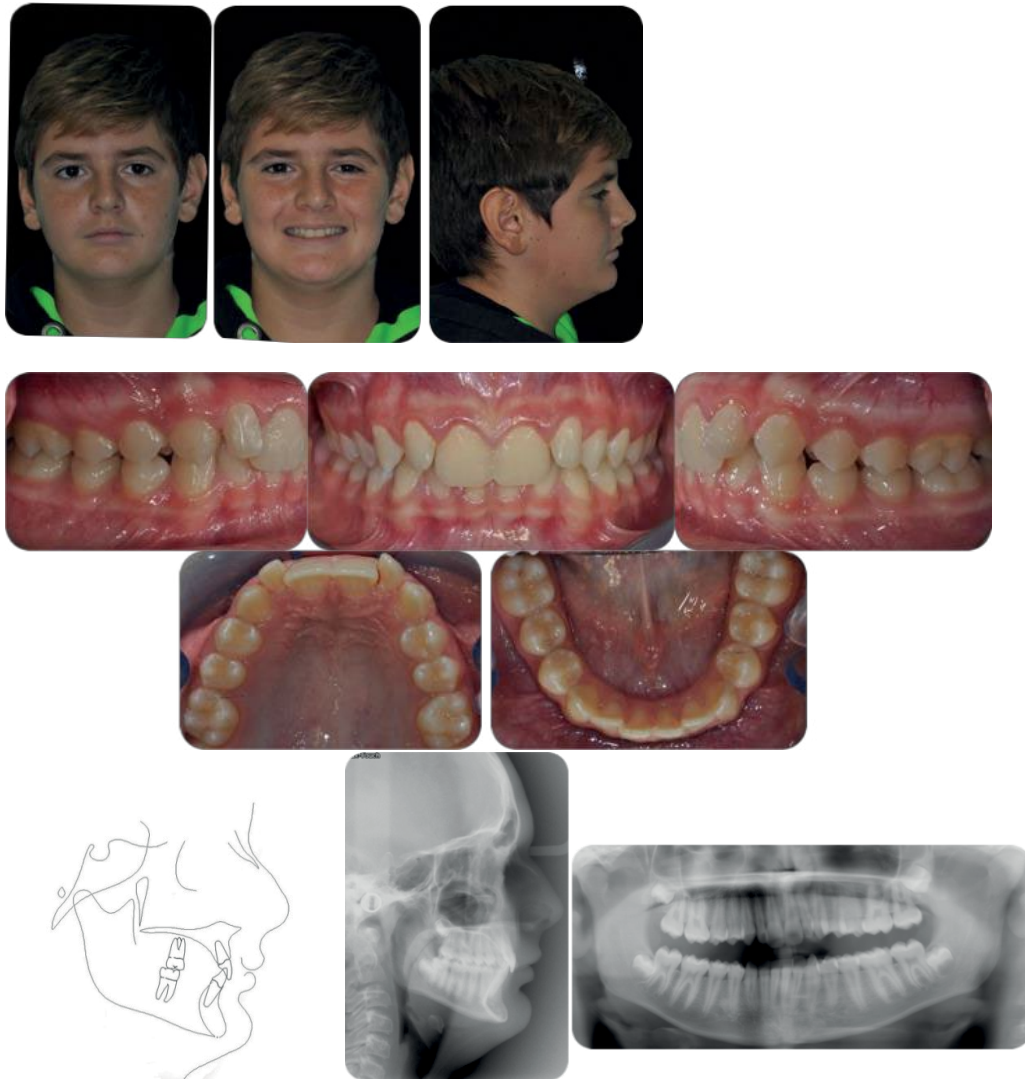
### Case 1

**Diagnosis and etiology:** A 13-year-old male patient came to the orthodontic clinic with a severe Class II div. 2, deep bite and mild crowding in both arches. The radiographic and clinical examinations of the temporo-mandibular joints showed no alterations. The patient was diagnosed with a dento-skeletal Class II div. 2 malocclusion, dental deep bite and a mandibular retrusion. He reported bilateral molar and canine Class II, -5 mm of deep bite, no overjet, severe palatal inclination of the upper incisors and coincident midlines. His facial features consisted of: concave profile for an evident retrusion of both maxilla and mandible.

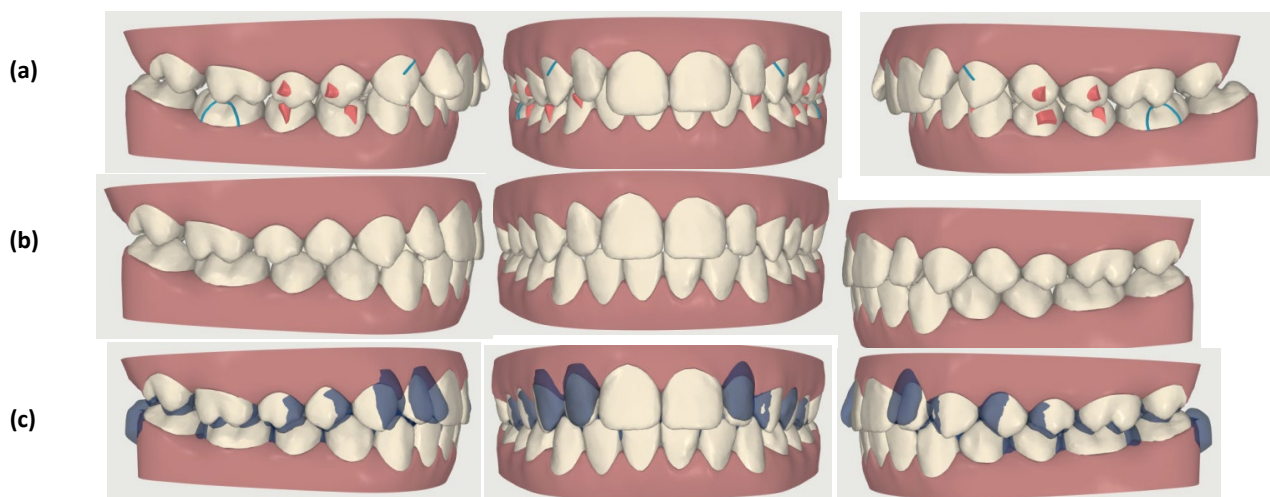
**Treatment objectives:** The main treatment objectives were:

- to correct the Class II dento-skeletal relationship;
- to obtain an ideal overbite and overjet;
- to promote an anterior repositioning of the mandible.

Additional treatment goals included leveling and aligning, optimizing the posterior occlusion, aiming at Class I molar and canine relationship, improving the facial profile and obtaining a natural lip position (**Figures 6 and 7**).



**Figure 6** Initial records.



**Figure 7** Virtual simulation of A-P changes: (a). Initial (b). Final (c). Pre/Post superimposition.

**Treatment plan:** The Invisalign® option was selected for comfort and aesthetic advantages. Treatment started with the correction of any mesial rotation of upper 1st and 2nd molars and an expansion of both arches to allow coordination between arches and to favor bicuspid and canines into Class I relationships.

The attachments in the upper arch were programmed to perform the anchorage unit necessary to allow the torque correction of the upper incisors. Furthermore, the attachments in both arches were designed to modify the tipping of bicuspid in order to improve the occlusion.

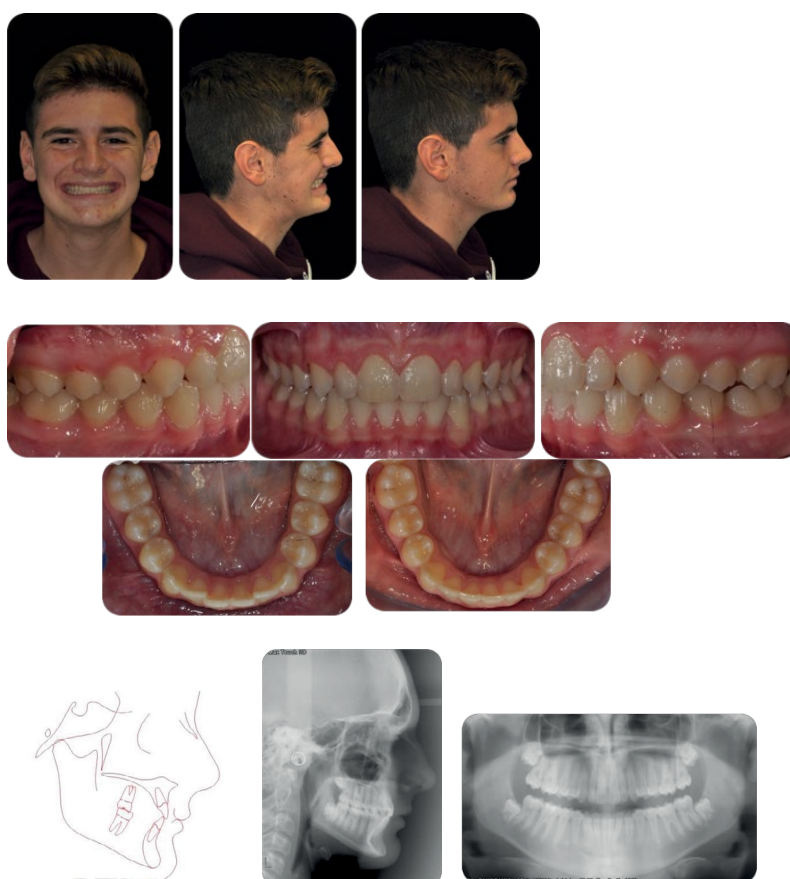During the first phase of treatment, Class II elastics were tied from a hook in the upper aligner to the bonded metal button on the buccal surface of the lower first molars with 4 oz, 3/16 size elastics, to improve upper molars' distal rotation. Upon refinement phase, in order to allow the mandible's anterior repositioning, Class II elastics were tied from a clear bonded button onto the surface of the upper canines to the metal button on the lower first molars.

**Treatment progress:** Digital models were taken by ITERO® scanner and the case was submitted for Invisalign Full®. The correction occurred by means of a first phase of 14 aligners and a finishing stage with 10 aligners. In phase one, the initial correction was achieved by means of distal rotation of upper molars, expansion of both arches and upper incisors' torque modification.

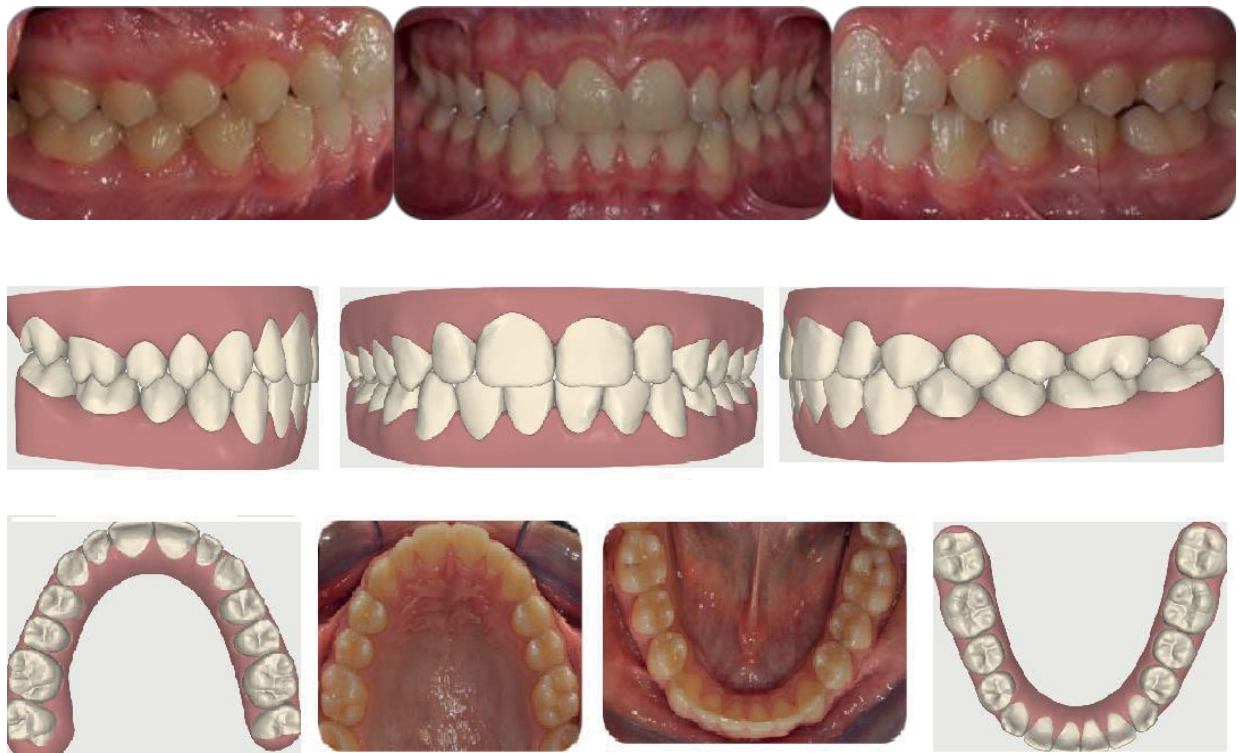Upon the refinement phase, the upper arch expansion,

together with the correction of the incisors' torque, allowed the coordination of both arches and anterior mandibular repositioning, successfully correcting the Class II malocclusion.

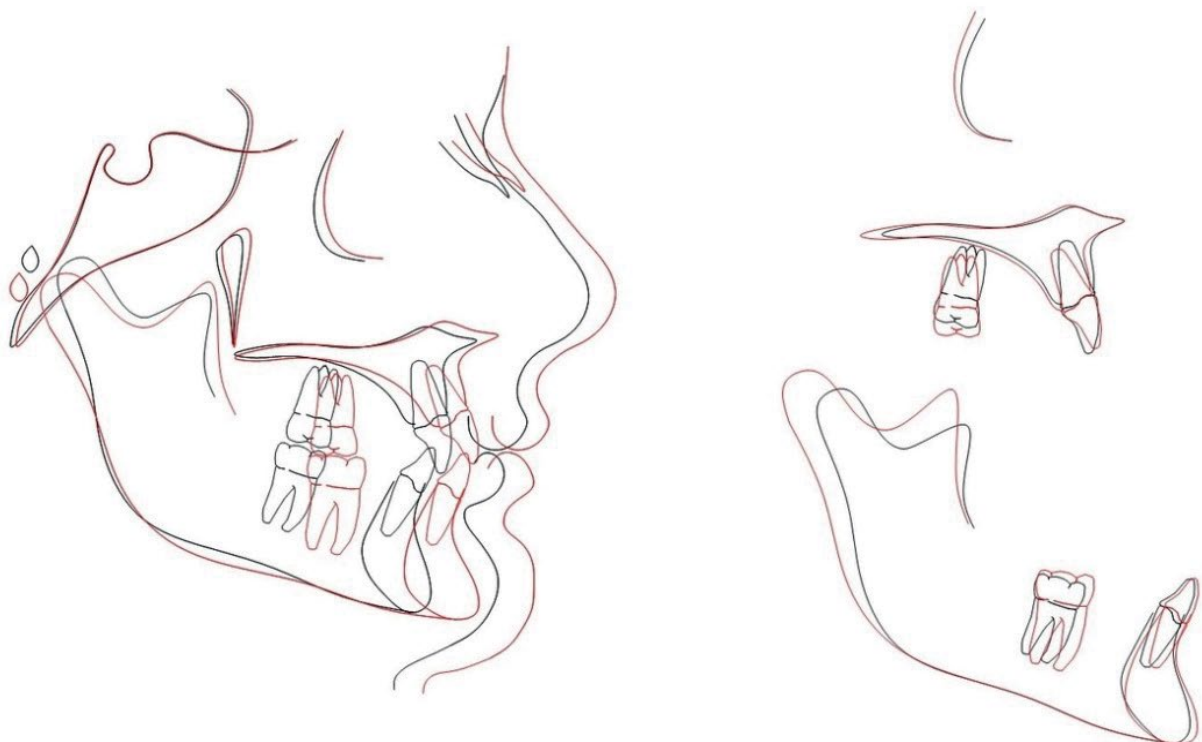
**Treatment results:** After 13 months of therapy, treatment objectives set in the pretreatment plan were achieved. The Class II malocclusion had been completely corrected; proper overbite and overjet were achieved. In particular, the overbite was reduced from 5 to 2 mm. Upon comparing, the virtual and the real outcomes correspond in the final result. Moreover, this treatment enables us to observe how the virtual jump programmed in the ClinCheck® simulation with the aid of the Class II elastics was actually clinically achieved. The pre and post-treatment cephalometric superimposition shows an evident change of the upper incisors' torque confirming the effectiveness of Power Ridge® auxiliary in the aligners: the maxillary incisors' inclination on the ANS-PNS plan changed from 104° to 115° and the mandibular incisors' inclination on Go-Gn increased from 93° to 101°. The Interincisal Angle changed from 145° to 128°. Such dental movement resulted in a mandibular anterior repositioning, mainly responsible for the correction of the Class II malocclusion as the pre and post-cephalometric superimposition shows. The mandibular position S-N/Pg changed from 78° to 82° and the N-A/Pg sagittal jaw relationship was modified from 4° to 1°. The facial growth was favorable and contributed to the correction of the malocclusion. The extraoral records show a slight improvement of the profile (Figures 8-10 and Table 1).



**Figure 8** Final records.



**Figure 9** Comparison real vs. virtual result.

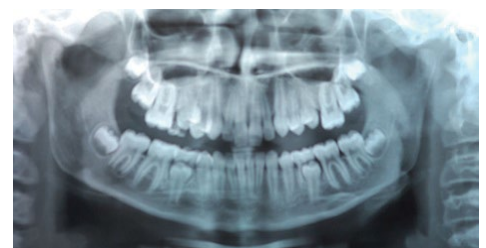
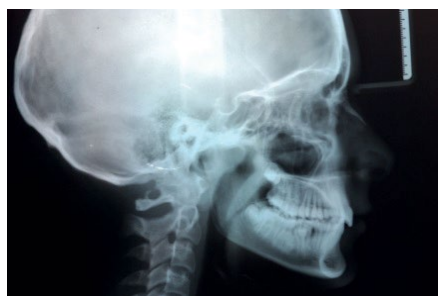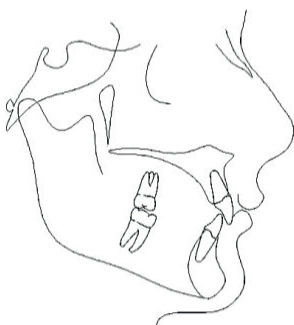

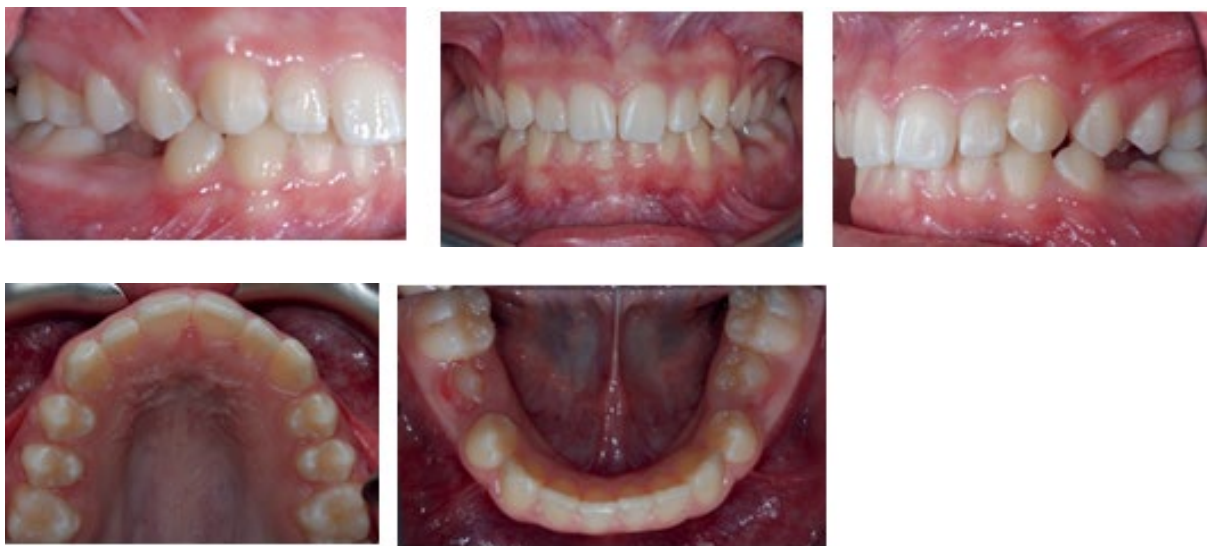
**Figure 10** Pre-Post cephalometric tracing superimposition.

**Table 1** Cephalometric morphological assessment.

CEPHALOMETRIC MORPHOLOGICAL ASSESSMENT	MEAN SD	PRE TREATMENT	POST TREATMENT
<b>SAGITTAL SKELETAL RELATIONS</b>	*****	*****	*****
Maxillary Position S-N-A	82°	80°	81°
Mandibular Position S-N-PG	80°	78°	82°
Sagittal Jaw Relation A-N-PG	2°	4°	1°
<b>VERTICAL SKELETAL RELATIONS</b>	*****	*****	*****
Maxillary Inclination S-N/ANS-PNS	8°	10°	5°
Mandibular Inclination S-N/Go-Gn	33°	31°	22°
Vertical Jaw Relation ANS-PNS/Go-Gn	25°	26°	17°
<b>DENTO-BASAL RELATIONS</b>	*****	*****	*****
Maxillary Incisor Inclination 1/ANS-PNS	110°	104°	115°
Mandibular Incisor Inclination 1/Go-Gn	94°	93°	101°
Mandibular Incisor Compensation 1/A-Pg (mm)	2	1	1
<b>DENTAL RELATIONS</b>	*****	*****	*****
Overjet (mm)	3.5	1	0
Overbite (mm)	2	5	2
Interincisal Angle 1/1	132°	145°	128°

**Case 2**  
**Diagnosis and etiology:** A 12-year-old female patient came to the orthodontic clinic with a Class II Div. 1 deep bite and slight crowding in the upper arch. The patient was diagnosed with a dental Class II div. 2 malocclusion, over deep bite and a mandibular retrusion. She reported bilateral Class II molar and canine, over deep bite, 4 mm of overjet, palatal inclination of the upper incisors and no coincident midlines. Facial features consisted of a balanced profile with a retrognathic tendency (**Figure 11**).

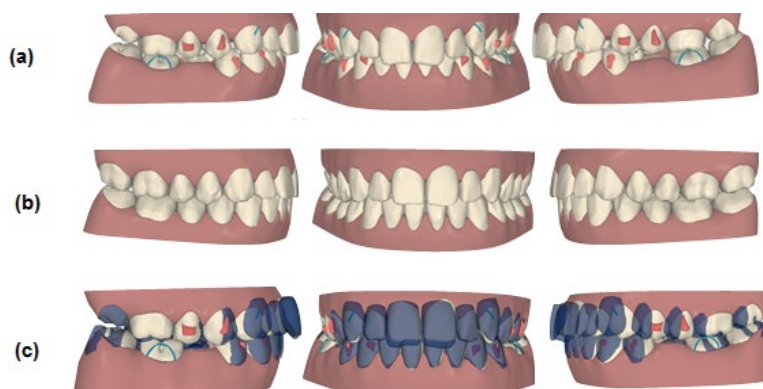


**Figure 11** Initial records.

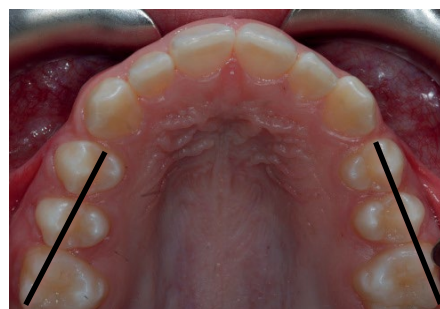
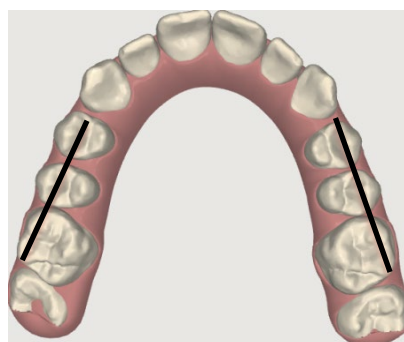
**Treatment objectives:** The main treatment objectives were:

1. to correct Class II dento-skeletal relationship;
2. to obtain an ideal overbite and overjet;
3. to promote an anterior repositioning of the mandible.

Additional treatment goals included leveling and aligning, optimizing the posterior occlusion, aiming at Class I molar and canine relationship, improving the facial profile and obtaining a natural lip position (**Figures 12 and 13**).



**Figure 12** Virtual simulation of sagittal changes: (a). Initial (b): Final (c): Pre/Post Superimpositions.



**Figure 13** Mesiorotation of the upper molars upon initial observation.

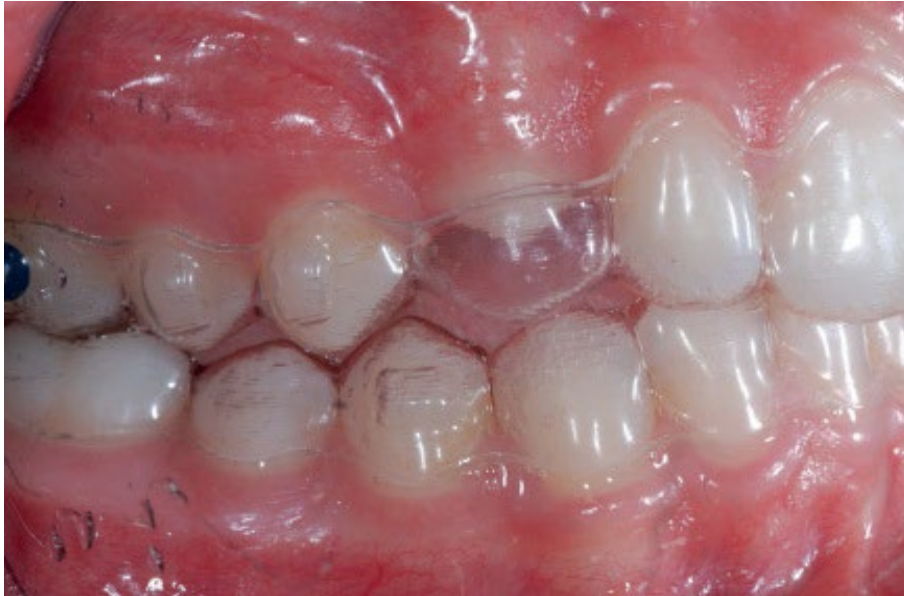**Treatment plan:** Treatments with fixed appliances could have been indicated to help correct the Class II molar, while controlling the upper and lower incisors' torque easily, meanwhile improving the overbite and overjet. Extractions were not indicated in order to correct the Class II relationship as the patient showed a retrognathic tendency. Thus, the patient was given the options of Invisalign treatment or conventional fixed appliances.

The Invisalign® option was selected for comfort and aesthetic advantages. In addition, it was also considered to be less invasive. It is important to offer the choice between aligners and conventional fixed appliances to the patient, when appropriate. Careful case selection is critical because of the increased need for patient compliance and cooperation when wearing aligners. Digital models were taken by ITERO® scanner and the case was submitted for Invisalign Teen. Cutouts were requested at the mandibular first molars, brackets were bonded for the use of Class II elastics, and the elastics were utilized upon initial delivery. The patient was given 3 sets of aligners at a time, and was seen every 6 weeks. The treatment was completed after 18 months.

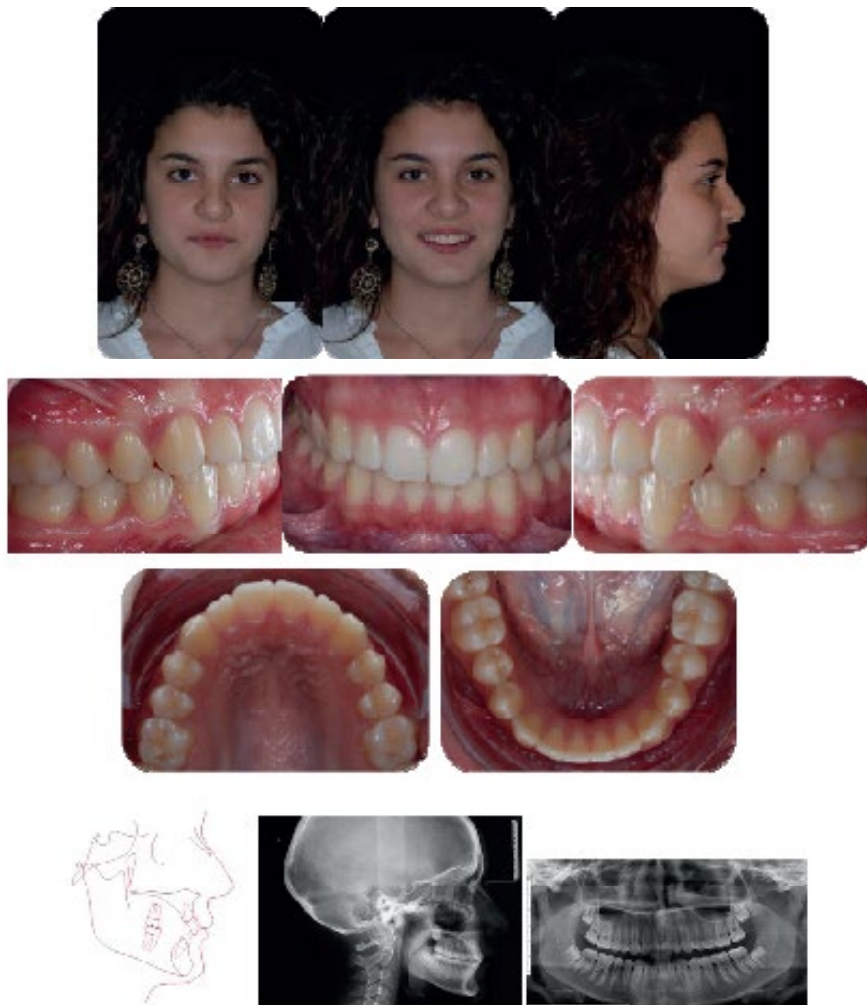
No case refinements were needed. Vivera® clear retainers were dispensed at the end of treatment.

**Treatment results:** The Class II malocclusion was corrected to a Class I relationship with ideal overjet and overbite. Good tooth alignment was accomplished. Interproximal Reduction (IPR) was not required. The maxillary width and archform were balanced. The midlines were corrected. Upon comparing, the virtual and the real outcomes corresponded in the final result. Panoramic evaluation showed no changes in the tooth root shapes, including the maxillary centrals. Cephalometric imaging and cephalometric superimpositions revealed there was a small amount of mandibular growth that contributed to the Class II correction. The maxillary incisors were uprighted and properly torqued to a more normal and pleasant position. The maxillary incisors' inclination on the ANS-PNS plan changed from 129° to 110° and the mandibular incisors' inclination on Go-Gn increased from 95° to 99°. The Interincisal Angle changed from 131° to 130°. There was essentially no vertical eruption of the molars contributing to the Class II correction (**Figures 14-17 and Table 2**).

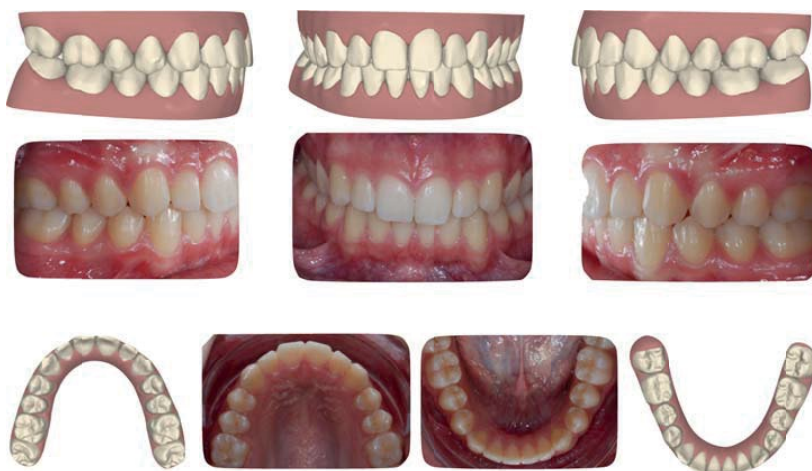



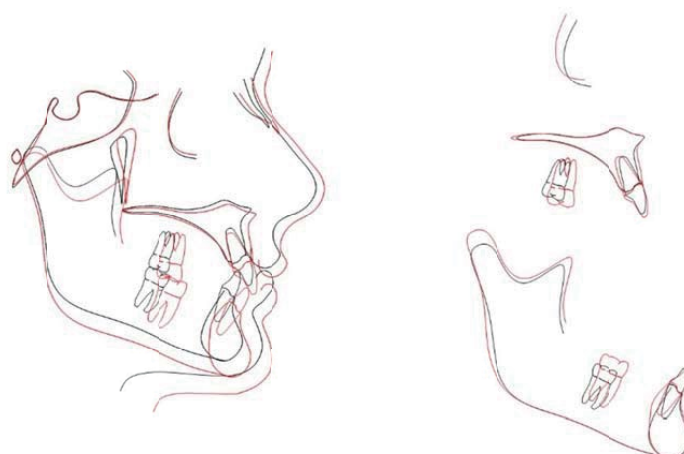
**Figure 14** Invisalign® Teen including compliance indicator and virtual geometry.



**Figure 15** Final records.



**Figure 16** Comparison real vs. virtual result.



**Figure 17** Pre-Post cephalometric tracing superimpositions.

**Table 2** Cephalometric morphological assessment.

CEPHALOMETRIC MORPHOLOGICAL ASSESSMENT	MEAN SD	PRE	POST
		TREATMENT	TREATMENT
<b>SAGITTAL SKELETAL RELATIONS</b>	*****	*****	*****
Maxillary Position S-N-A	82°	80°	80°
Mandibular Position S-N-PG	80°	77°	79°
Sagittal Jaw Relation A-N-PG	2°	3°	1°
<b>VERTICAL SKELETAL RELATIONS</b>	*****	*****	*****
Maxillary Inclination S-N/ANS-PNS	8°	15°	16°
Mandibular Inclination S-N/Go-Gn	33°	29°	33°
Vertical Jaw Relation ANS-PNS/Go-Gn	25°	14°	17°
<b>DENTO-BASAL RELATIONS</b>	*****	*****	*****
Maxillary Incisor Inclination 1/ANS-PNS	110°	129°	110°
Mandibular Incisor Inclination 1/Go-Gn	94°	95°	99°
Mandibular Incisor Compensation 1/A-Pg (mm)	2	1°	0°
<b>DENTAL RELATIONS</b>	*****	*****	*****
Overjet (mm)	3.5	2	1
Overbite (mm)	2	4	2.5
Interincisal Angle 1/1	132°	131°	130°

## Discussion

Orthodontic treatment with fixed appliances implies certain inherent drawbacks including increased oral bacteria, dental and soft-tissue discomfort, and poor esthetics. Adolescents may be particularly reluctant to undergoing fixed-appliance treatment for social reasons, but doctors and parents have been dubious about their willingness to cooperate upon use of removable clear aligners. However, in orthodontic correction of Class II malocclusion by aligners, clinicians can achieve excellent results by adopting the same treatment protocol currently used with conventional fixed appliances. In ClinCheck®'s digital environment, just as in conventional orthodontics, we shall program the same dental movements that are needed to make the two dental arches compatible. Then, the use of Class II elastics allows a mesial mandibular repositioning and, thanks to the compatibility of the dental arches, stabilization of the final result is possible. Nevertheless, according to Rossini et al. the accuracy of the bucco-lingual movements in the anterior segments is lower than in posterior segments, thus supporting the common practice of inserting 10° of additional torque at front teeth. Such measure can be strictly recommended in cases of Class II with deep bite in which reaching a proper incisor torque represents an elective treatment goal. Moreover, Invisalign® treatment provides some advantages over fixed appliances in specific cases. In the presented cases, treatment duration (18 months) was highly satisfactory, because the Class II elastics were worn upon initial delivery. By contrast, when using Class II elastics along with fixed appliances, it generally takes several months to be able to utilize wires that are of sufficient size and strength. Also, when using Class II elastics along with fixed appliances, there can be canting of the occlusal plane because of the resulting vertical component of force. Since the occlusal surfaces are completely covered, Invisalign® allows for the elimination or reduction of the typical "Class II elastic effect." Although further research needs to be carried out, it appears that clear aligner treatment potentially causes less root resorption than conventional fixed appliances. This makes it an ideal choice for teeth that may be susceptible to root resorption.

## Conclusion

At the beginning of the "digital era," the majority of orthodontists thought that aligners were not the ideal tool for treating Class II malocclusions. After 10 years of experience, this article intends to show how it can be performed in a simple and predictable way. However, a proper diagnosis and treatment planning are fundamental in order to correct dental-skeletal Class II by using aligners. Moreover, in order to exploit the best effectiveness of aligners, thorough knowledge and experience in dental biomechanics are necessary. Correction of the malocclusion can be a crucial step to achieve the desired occlusal, functional and cosmetic result. This treatment method is not merely limited to the re-alignment of malposed teeth, but can also successfully correct Class II occlusal relationships.

## References

- 1 Pancherz H, Zieber K, Hoyer B (1997) Cephalometric characteristics of Class II division 1 and Class II division 2 malocclusions: a comparative study in children. *Angle Orthod* 67: 111-120.
- 2 McNamara JA Jr (1981) Components of Class II malocclusion in children 8-10 years of age. *Angle Orthod* 51: 177-202.
- 3 Ngan PW, Byczek E, Scheick J (1997) Longitudinal evaluation of growth changes in Class II Division 1 subjects. *Semin Orthod* 3: 222-231.
- 4 Buschang PH, Tanguay R, Demirjian A, LaPalme L, Turkewicz J (1988) Mathematical models of longitudinal mandibular growth for children with normal and untreated Class II, division 1 malocclusion. *Eur J Orthod* 10: 227-234.
- 5 Baccetti T, Franchi L, McNamara JA Jr, Tollaro I (1997) Early dentofacial features of Class II malocclusion: a longitudinal study from the deciduous through the mixed dentition. *Am J Orthod Dentofacial Orthop* 111: 502-509.
- 6 Ngan PW, Byczek E, Scheick J (1997) Longitudinal evaluation of growth changes in Class II division 1 subjects. *Semin Orthod* 3: 222-231.
- 7 Stahl F, Baccetti T, Franchi L, McNamara JA Jr (2008) Longitudinal growth changes in untreated subjects with Class II Division 1 malocclusion. *Am J Orthod Dentofacial Orthop* 134: 125-137.
- 8 Liu D, Melsen B (2001) Reappraisal of class II molar relationships diagnosed from the lingual side. *Orthod Craniofac Res* 4: 97-104.
- 9 Lima BP, Pinzan-Vercelino CR, Dias LS, Bramante FS, Tavarez RR (2015) Correlation between the Rotation of the First Molars and the Severity of Class II Division 1 Malocclusion. *Sci World J* 2015: 261485.
- 10 Li P, Feng J, Shen G, Zhao N (2016) Severe Class II Division 1 malocclusion in an adolescent patient, treated with a novel sagittal-guidance Twin-block appliance. *Am J Orthod Dentofacial Orthop* 150: 153-166.
- 11 Giuntini V, Vangelisti A, Masucci C, Defraia E, McNamara JA Jr (2015) Treatment effects produced by the Twin-block appliance vs the Forsus Fatigue Resistant Device in growing Class II patients. *Angle Orthod* 85: 784-789.
- 12 Kinzinger GS, Lisson JA, Frye L, Gross U, Hourfar J (2017) A retrospective cephalometric investigation of two fixed functional orthodontic appliances in class II treatment: Functional Mandibular Advancer vs. Herbst appliance. *J Clin Oral Investig* 2017 Apr 1. doi: 10.1007/s00784-017-2111-5. [Epub ahead of print]
- 13 Tomblyn T, Rogers M, Andrews L, Martin C, Tremont T (2016) Cephalometric study of Class II Division 1 patients treated with an extended-duration, reinforced, banded Herbst appliance followed by fixed appliances. *Am J Orthod Dentofacial Orthop* 150: 818-830.
- 14 Hennessy J, Al-Awadhi EA (2016) Clear aligners generations and orthodontic tooth movement. *J Orthod* 43: 68-76.
- 15 Giancotti A, Di Girolamo R (2009) Treatment of severe maxillary crowding using Invisalign and fixed appliances. *J Clin Orthod* 43: 583-589.
- 16 Giancotti A, Mampieri G, Greco M (2008) Correction of deep bite in adults using the Invisalign system. *J Clin Orthod* 42: 719-726.
- 17 Giancotti A, Mampieri G (2012) Unilateral canine crossbite correction in adults using the Invisalign method: a case report. *Orthodontics* 13: 122-127.

- 18 Fisher K (2010) Invisalign treatment of dental Class II malocclusions without auxiliaries. *J Clin Orthod* 44: 665-672.
- 19 Schupp W, Haubrich J, Neumann I (2010) Class II correction with the Invisalign system, *J Clin Orthod* 44: 28-35.
- 20 Bowman SJ, Celenza F, Sparaga J, Papadopoulos MA, Ojima K (2015) Creative adjuncts for clear aligners, part 1: Class II treatment. *J Clin Orthod* 49: 83-94.
- 21 Schupp W, Haubrich J (2016) *Aligner Orthodontics: diagnostic, biomechanics, planning and treatment*. Quintessence Publishing, USA.
- 22 Rossini G, Parrini S, Castroflorio T, Deregibus A, Debernardi C (2015) Efficacy of clear aligners in controlling orthodontic tooth movement: A systematic review. *Angle Orthod* 85: 881-889.